



Research Article

Are MRI Findings of Gallbladder Bile Associated with Gallbladder Stone Formation?

 Erdem Yilmaz

Department of Radiology, Trakya University Faculty of Medicine, Edirne, Turkey

Abstract

Objectives: The aim of the present study was to evaluate the possible association between the hyperintense saturated appearance of the gallbladder bile on T1-weighted magnetic resonance imaging (MRI) in the fasting state and the development of gallbladder stone on follow-up.

Methods: We evaluated 100 consecutive MRIs in the fasting state that have follow-up MRI but not gallbladder stone. On T1-weighted images, hyperintense and hypointense groups were formed according to gallbladder contents. Follow-up MRIs were evaluated in terms of gallbladder stone development. The groups with and without gallbladder stones were compared according to follow-up time.

Results: Gallbladder contents on MRI in the fasting state were T1 hyperintense in 85 patients and T1 hypointense in 15 patients. There was no statistically significant difference about the development of gallbladder stone on follow-up between the T1 hyperintense group (n: 11, 12.9%) and the T1 hypointense group (n: 2, 13.3%) ($p=0.96$). There was no statistically significant difference about the follow-up time between the groups with and without the development of gallbladder stone ($p=0.20$).

Conclusion: There was no significant relationship between the concentrated appearance of the gallbladder bile on T1-weighted MRI in the fasting state and the development of gallbladder stone on follow-up. We believe that this probable relationship can be evaluated more clearly with prospective studies, larger populations, and long-term follow-up.

Keywords: Gallbladder, gallstones, magnetic resonance imaging

Cite This Article: Yilmaz E. Are MRI Findings of Gallbladder Bile Associated with Gallbladder Stone Formation?. EJMO. 2018; 2(4): 217-220

Although magnetic resonance imaging (MRI) is not the primary imaging modality for gallbladder, it is a successful imaging technique that provides anatomical, physiological and chemical data about gallbladder and biliary tract.^[1] In addition, abnormal bile can be evaluated more comprehensively with MRI than computed tomography and ultrasonography (USG).^[2] USG is an effective and the most preferred non-invasive method of screening gallstones, but it may not be sufficient to assess anatomic details in obese patients.^[3]

In previous studies, hyperintense gallbladder bile on T1-weighted images was shown caused by bile saturation in fasting state.^[1, 4] Absorption of water in the gallbladder during fasting causes increased cholesterol and bile salt concentration in the bile, shortening the T1 relaxation

time and increased T1 signal intensity.^[3] To the best of our knowledge, the possible association between the appearance of intense bile and gallstone development has not been evaluated before. The aim of our study was to examine this possible relationship with follow-up MRI.

Methods

This was a retrospective, descriptive study. The study has been approved from the ethics committee of our hospital. One hundred consecutive patients with MRI in fasting state were included to the study that have follow-up MRI. The exclusion criterias as follows; patients that have gallbladder stone or sludge in first MRI, collapsed gallbladder, acute and chronic cholecystitis, gallbladder removal surgery, primary gallbladder tumors or tumors that extend to gallblad-

Address for correspondence: Erdem Yilmaz, MD. Trakya Universitesi Tıp Fakültesi, Radyoloji Anabilim Dalı, Balkan Yerleşkesi, 22030 Edirne, Turkey

Phone: +90 284 236 09 09 - 1666 **E-mail:** yilmazerdem79@yahoo.com.tr

Submitted Date: July 12, 2018 **Accepted Date:** September 13, 2018 **Available Online Date:** October 10, 2018

©Copyright 2018 by Eurasian Journal of Medicine and Oncology - Available online at www.ejmo.org



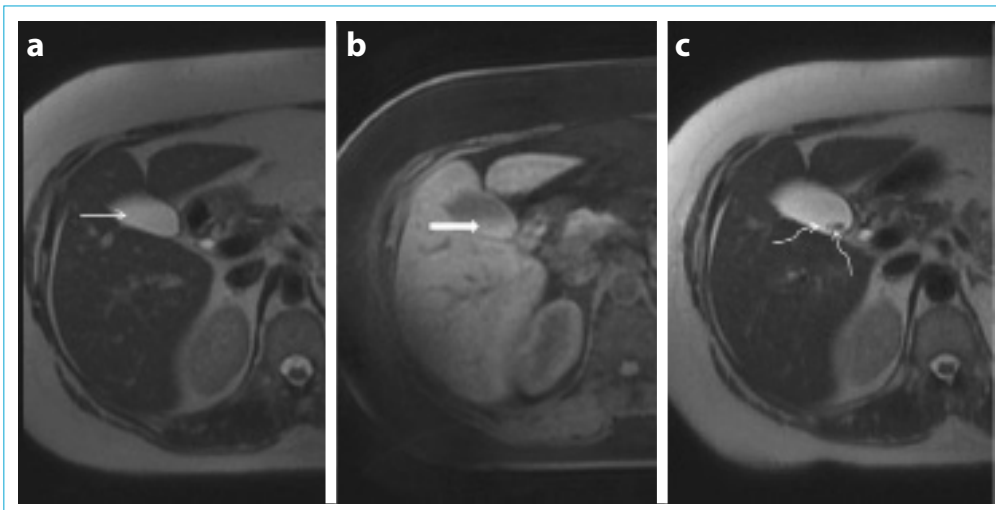


Figure 1 (a–c). 49 year-old female patient **(a)** In axial T2-weighted image, gallbladder lumen content is hyperintense (thin arrow). **(b)** In axial T1-weighted image, saturated hyperintense bile level (thick arrow) is seen in gallbladder lumen. **(c)** In axial T2-weighted image, T2 hypointense gallstones (curved arrows) with a diameter of 5 mm are observed on follow-up MRI in 41 months.

der, trauma history, and patients with low quality MRI. Only one radiologist (EY, 13 year of abdominal imaging experience) evaluated the MRI findings.

MRI of the abdomen was performed with a 1.5 Tesla MR machine (Signa HDxt Excite II; GE Medical Systems, Waukesha, WI, USA). The duration of fasting state before MRI was at least 9 hours. MRI signals were obtained with 8-channel body coils. T2-weighted images were obtained with fast spin echo sequence (repetition time (TR) / echo time (TE)=3440/87 ms, slice thickness=6 mm, field of view (FOV)=430 mm, matrix=320x224, number of excitations (NEX)=2) on axial and coronal planes. T1-weighted images (repetition time (TR) / echo time (TE)=145/3.7 ms, slice thickness=6 mm, field of view (FOV)= 430 mm, matrix=320x160, number of excitations (NEX)=1) were obtained on axial plane. USG was performed using a 5 MHz convex and 10 MHz linear probe (Mylab 70 XVG; Esaote Medical Systems, Genova, Italy).

T1 hyperintense and T1 hypointense gallbladder groups were created according to gallbladder contents on fasting state. Axial T2, coronal T2, axial T1 sequences of follow-up MRI were investigated in terms of gallstone development. The cases with USG examinations were evaluated for gallstone development. Two groups were compared in terms of gallstone development during follow-up. The follow-up period of two groups were compared. Analysis of the categorical data using the SPSS 16.0 for Windows program was done by chi-square test, expressed in frequency and percentage. Numerical data were analyzed by Mann Whitney U test. A value of $p < 0.05$ was considered statistically significant.

Results

Gallbladder contents on MRI in fasting state were T1 hyperintense in 85 patients (Fig. 1) and T1 hypointense in 15 patients (Fig. 2). The age, gender, imaging and follow-up findings of the patients were shown in Table 1. T1 hyperintense and T1 hypointense groups according to gallbladder content were similar in terms of age and sex.

Gallbladder stone developed in 11 patients (12.9%) with T1 hyperintense group, and in 2 patients (13.3%) with T1 hypointense group. There was no statistically significant difference between the groups in terms of gallbladder stone development ($p=0.96$). During the follow-up period, USG examinations were performed in 59 patients. 8 of 13 patients that developed gallstone in follow-up period had USG, and gallstones were seen in all of them.

Median follow-up time was 24.5 months. There was no statistically significant difference in follow-up period between gallstone development group and non-development group on T1 hyperintense and T1 hypointense patients ($p=0.20$) (Table 1).

Discussion

The bile fluid produced in the liver predominantly contains water which is hypointense in T1-weighted sequence and hyperintense in T2-weighted sequence.^[4, 5] Gallbladder accumulates the bile. The water in the bile fluid is absorbed at the gallbladder and the bile fluid is saturated.^[1, 3] Thus, bile fluid contains bile acid, phospholipid, cholesterol at high concentration. If the gallbladder motility decreases and the resistance of the cystic channel increases, gallbladder bile

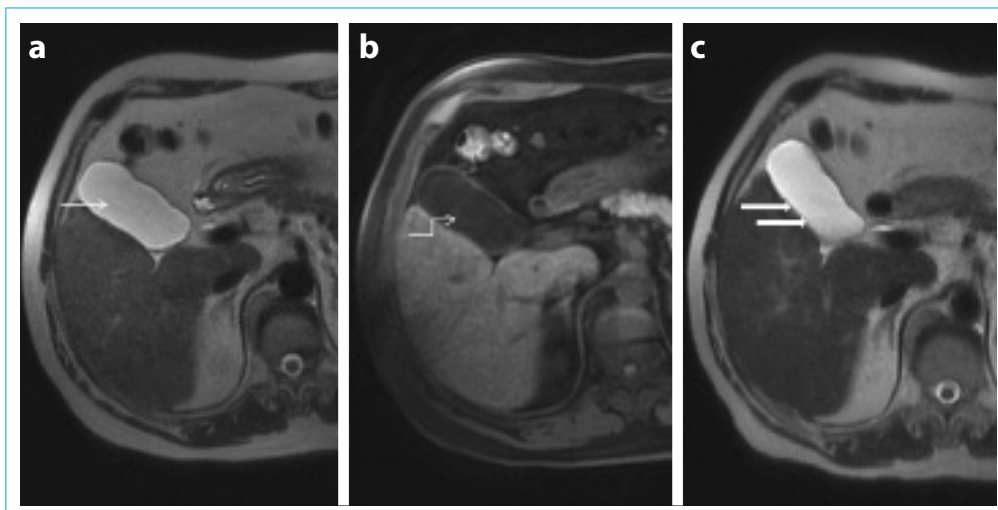


Figure 2 (a–c). 52 year-old male patient. **(a)** In axial T2-weighted image, gallbladder lumen content is hyperintense (thin arrow). **(b)** In axial T1-weighted image, gallbladder lumen content is hypointense (angled arrow). **(c)** In axial T2-weighted image, there is no gallstone on follow-up MRI in 20 months.

Table 1. Demographic and clinic characteristics of patient groups

	All patients (n=100)	T1 hyperintense group (n=85)	T1 hypointense group (n=15)	p
Gender, (F/M)	58/42	52/33	6/9	0.12
Age, median (min-max)	57 (24–85)	56 (24–85)	58 (41–55)	0.28
Development of gallstone, n (%)	13 (13%)	11 (12.9%)	2 (13.3%)	0.96
Follow-up (month), median (min.–max.)				
All patients	24.5 (6–61)	24 (6–61)	32 (6–60)	0.20
Development of gallstone	29 (15–58)	29 (17–58)	34 (15–53)	0.76
Non-development of gallstone	24 (6–61)	24 (6–61)	32 (6–60)	0.16
USG, n (%)	59 (59)	47 (55.3)	12 (80)	0.13

F: Female; M: Male; Min.: Minimum; Max.: Maximum; USG: Ultrasonography.

will be excessively saturated. Crystal precipitates, cholesterol deposits, gallstones containing 1–3 mm particles called microliths and ultimately gallstones will develop.^[3, 6, 7]

Saturated bile content on fasting state shortens T1 time and causes T1 hyperintense appearance on MRI.^[4] However, changes in the appearance of T1 intensities due to differences in bile concentration, and hyper-hypointense levels in T1- and T2-weighted studies are frequently seen.^[2]

³⁾ In our study, gallbladder content was T1 hyperintense in 85 patients (85%), and T1 hypointense in 15 patients (15%). Although development of gallbladder stone were higher in T1 hyperintense group on follow-up, there was no statistically significant difference between T1 hyperintense and T1 hypointense groups.

Saturated bile is seen as T1 hyperintensity that fills the gallbladder lumen or hyperintense-hypointense bile level on fasting state MRI.^[1, 4] According to the content of the sludge and stone, they can be seen as hypointense in T2-weight-

ed image, and variable intensities in T1-weighted images. Spheric, ovoid or irregular shaped stones may accumulate in the lower part of the gallbladder lumen.^[2, 3, 8–11] While most of the pigmented gallstones are shown as T1 hyperintense, all cholesterol gallstones are T1 hypointense.^[12] Although it is not clear why the hyperintensity is observed in the T1 sequence, it is thought that metal ions in the pigment stones may be responsible.^[13, 14]

After the meal, saturated gallbladder content drains into the duodenum. Hepatic bile which contains high percentage of water pours into gall bladder and T1-weighted MRI examination reveals hypointense bile in gallbladder lumen. Also gallbladder diseases, such as chronic cholecystitis, in which bile fluid can not be saturated, may also have a hypointense appearance in T1-weighted images.^[11] In our study, gallbladder lumen was T1 hyperintense in the vast majority of the cases in fasting state, the gallbladder contents were seen as T1 hypointense in 15% of the patients. T1 hypointense ap-

pearance in these patients may be due to the insufficiency of bile saturation mechanism in comparison to T1 hyperintense patient group. Another cause may be gallbladder diseases such as chronic cholecystitis. However, our study did not include chronic cholecystitis patients.

Gallbladder imaging should be performed after fasting for 8–12 hours which provides luminal physiological distention.^[3] In our study, the duration of fasting state before MRI was at least 9 hours. There was no statistically significant difference in gallstone development in follow-up between T1 hyperintense and T1 hypointense groups. Longer fasting state studies may be useful to compare these groups for development of gallbladder stone.

Although MRI is quite successful in detecting gallbladder and bile duct stones, very small stones which are of less than 2 mm in size may not be shown.^[15] For this reason, USG findings were also evaluated in our study. However, USG was performed in 59 patients. 8 of 59 patients that gallbladder stone developed in follow-up were detected also by USG. Other 5 patients with gallstone development didn't have USG examination. Due to technical improvements in MRI, image quality is increased, However, optimal imaging may not be possible due to artefacts due to respiration, intestinal peristalsis, and vascular pulsations. Artefacts also can cause false interpretations.^[16] Patients who did not have adequate image quality were not included to our study.

This study had several limitations. One of the limitation was due to retrospective study design leading to uncontrolled data about confounding factors and absence of clinical characteristics (diet, BMI etc.) of patients related to gallbladder stone formation. The other major limitation were small number of patients during follow-up time, and lack of USG findings in some patients. In addition, the pathologic confirmation was absent in patients with gallbladder stone. Due to fact that the patients did not have any symptoms related to gallbladder stone in their hospital records, no surgical intervention was performed. Due to the only one radiologist's evaluation, inter and intraobserver variability were not shown.

In conclusion, there was no significant relationship between saturated appearance of gallbladder bile on T1 weighted MRI in fasting state and development of gallbladder stone on follow-up. This probable relationship can be evaluated more clearly with prospective studies, larger populations and long-term follow-up.

Disclosures

Ethics Committee Approval: The study was approved by the Local Ethics Committee.

Peer-review: Externally peer-reviewed.

Conflict of Interest: None declared.

References

- Hricak H, Filly RA, Margulis AR, Moon KL, Crooks LE, Kaufman L. Work in progress: nuclear magnetic resonance imaging of the gallbladder. *Radiology* 1983;147:481–4. [\[CrossRef\]](#)
- Lee NK, Kim S, Lee JW, Lee SH, Kang DH, Kim DU, et al. MR appearance of normal and abnormal bile: correlation with imaging and endoscopic finding. *Eur J Radiol* 2010;76:211–21.
- Catalano OA, Sahani DV, Kalva SP, Cushing MS, Hahn PF, Brown JJ, et al. MR imaging of the gallbladder: a pictorial essay. *Radiographics* 2008;28:135–55. [\[CrossRef\]](#)
- Demas BE, Hricak H, Moseley M, Wall SD, Moon K, Goldberg HI, et al. Gallbladder bile: an experimental study in dogs using MR imaging and proton MR spectroscopy. *Radiology* 1985;157:453–5. [\[CrossRef\]](#)
- Bader TR, Semelka RC. Gallbladder and biliary system. In: Semelka RC, editor. *Abdominal-pelvic MRI*. New York: Wiley-Liss; 2002. p. 447–507.
- Pitt HA, Doty JE, DenBesten L, Kuchenbecker SL. Stasis before gallstone formation: altered gallbladder compliance or cystic duct resistance? *Am J Surg* 1982;143:144–9. [\[CrossRef\]](#)
- Jüngst C, Kullak-Ublick GA, Jüngst D. Gallstone disease: Microlithiasis and sludge. *Best Pract Res Clin Gastroenterol* 2006;20:1053–62. [\[CrossRef\]](#)
- Schneider G, Grazioli L, Saini S. Imaging of the biliary tree and gallbladder diseases. In: Schneider G, Grazioli L, Saini S, editors. *MRI of the liver*. 2nd. Heidelberg: Springer; 2005. p. 237–66.
- Sahani DV, Kalva SP. Magnetic resonance imaging of the gallbladder. In: Edelman RR, Hesselink JR, Zlatkin MB, Cruess VC, editors. *Clinical magnetic resonance imaging*. 3rd. Philadelphia: Saunders; 2005. p. 2541–53.
- Baron RL, Shuman WP, Lee SP, Rohrmann CA Jr, Golden RN, Richards TL, et al. MR appearance of gallstones in vitro at 1.5 T: correlation with chemical composition. *AJR Am J Roentgenol* 1989;153:497–502. [\[CrossRef\]](#)
- Moeser PM, Julian S, Karstaedt N, Sterchi M. Unusual presentation of cholelithiasis on T1-weighted MR imaging. *J Comput Assist Tomogr* 1988;12:150–2. [\[CrossRef\]](#)
- Tsai HM, Lin XZ, Chen CY, Lin PW, Lin JC. MRI of gallstones with different compositions. *AJR Am J Roentgenol* 2004;182:1513–9.
- Ukaji M, Ebara M, Tsuchiya Y, Kato H, Fukuda H, Sugiura N, et al. Diagnosis of gallstone composition in magnetic resonance imaging: in vitro analysis. *Eur J Radiol* 2002;41:49–56. [\[CrossRef\]](#)
- Kim YK, Kim CS, Lee JM, Ko SW, Chung GH, Lee SO, et al. Value of adding T1-weighted image to MR cholangiopancreatography for detecting intrahepatic biliary stones. *AJR Am J Roentgenol* 2006;187:W267–74. [\[CrossRef\]](#)
- Romagnuolo J, Bardou M, Rahme E, Joseph L, Reinhold C, Barkun AN. Magnetic resonance cholangiopancreatography: a meta-analysis of test performance in suspected biliary disease. *Ann Intern Med* 2003;139:547–57. [\[CrossRef\]](#)
- Baillie J, Paulson EK, Vitellas KM. Biliary imaging: a review. *Gastroenterology* 2003;124:1686–99. [\[CrossRef\]](#)