

Original Image

Cardiac Invasion of HCC: Clinical Image

Osman Kostek,¹ Irem Karakaya Tosun,² Hande Tecimen,² Nil Su Kodall²

¹Department of Medical Oncology, Trakya University Faculty of Medicine, Edirne, Turkey ²Department of Internal Medicine, Trakya University Faculty of Medicine, Edirne, Turkey

Cite This Article: Kostek O, Tosun I, Tecimen H, Kodall N. Cardiac Invasion of HCC: Clinical Image. EJMO. 2017; 1(4): 243-243

Hepatocellular cancer (HCC) is the second leading cause of cancer-related deaths in the world. Advanced stage HCC requires systemic treatment. Extrahepatic metastasis may occur, and the lungs, abdominal lymph nodes, and bone are the most common sites of extrahepatic metastatic HCC. Unsuspected cardiac metastases may also be detected. Presently described is a rare case of cardiac invasion of advanced stage HCC.

A 57-year-old male patient had been diagnosed with advanced stage HCC and treated with sorafenib for 9 months. He was admitted to the medical oncology outpatient clinic with effort dyspnea and tachycardia. A chest X-ray showed

no abnormal radiological finding. Abdominal magnetic resonance imaging (MRI) revealed a hepatic tumoral mass extension into the heart. A cardiac MRI indicated that the mass was about 5.8 cm in size near the hepatic vein (Fig. 1a) and had reached into the right atrium via the vena cava inferior (Fig. 1b), filling the right atrium (6 cm in size) (Fig. 1c). The patient was referred to cardiovascular surgery.

The incidence of cardiac invasion of HCC is about 4.1%. One mechanism of cardiac metastasis is extension and vascular invasion of the tumor to the hepatic vein and the inferior vena cava, thus easily reaching the right cardiac cavities.

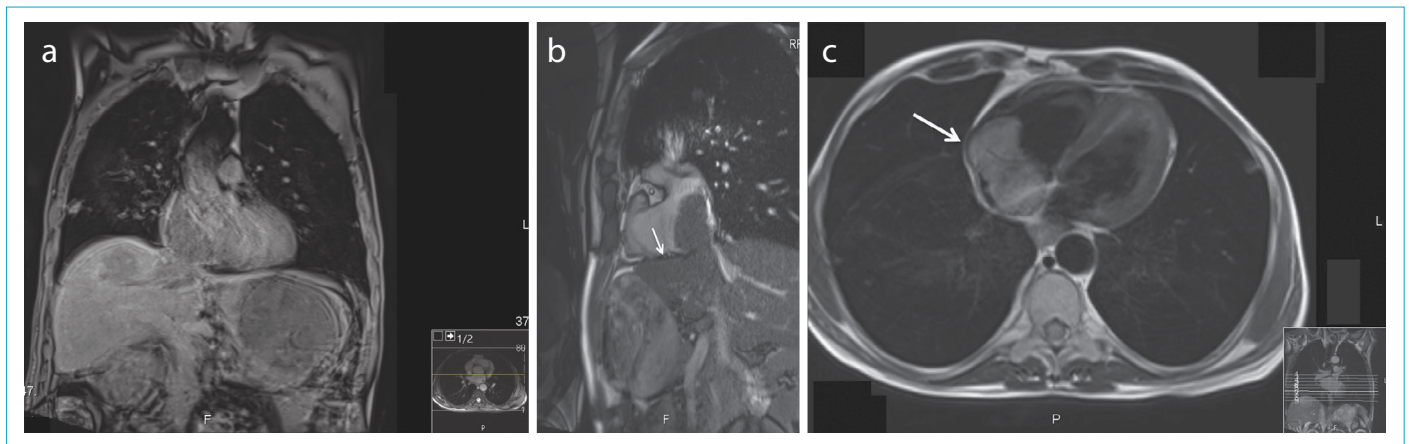


Figure 1. (a) The tumor was about 5.8 cm in size and located near the hepatic vein, (b) The tumor extension to the right atrium via the vena cava inferior, (c) The tumoral mass filled the right atrium (6 cm in size).

Address for correspondence: Osman Kostek, MD. Trakya Universitesi Tıp Fakültesi, İç Hastalıkları Anabilim Dalı, Edirne, Turkey

Phone: +90 284 236 09 09 **E-mail:** osmankostek@hotmail.com

Submitted Date: May 21, 2017 **Accepted Date:** July 20, 2017 **Available Online Date:** October 27, 2017

©Copyright 2017 by Eurasian Journal of Medicine and Oncology - Available online at www.ejmo.org

