

## Case Report

# The Reconstruction of The Anterior Thorax Wall After Sternal Resection Through the Combination of Autologous Fibula Graft and Metal Plate

 Serdar Ozkan

Department of Thoracic Surgery, Medova Hospital, Konya, Turkey

### Abstract

Despite rare entities, postoperative sternal osteomyelitis and mediastinitis are pathologies with high mortality that require certain surgical treatment. Even though many techniques are performed for the reconstruction of the sternal resection and anterior thorax wall, there is no accepted gold standard method yet. We present the reconstruction method we performed through the combination of free fibula autograft and metal plate.

**Keywords:** Fibula, reconstruction, sternal resection

**Cite This Article:** Ozkan S. The Reconstruction of The Anterior Thorax Wall After Sternal Resection Through the Combination of Autologous Fibula Graft and Metal Plate. *EJMO*. 2018; 2(4): 243-246

In many pathological conditions, such as primary and secondary tumors of sternum, sternal osteomyelitis, traumas and dehiscence after radionecrosis or sternotomy, the resection of sternal or anterior chest wall has been implemented. In such cases, the most serious approach is to perform the reconstruction in order to provide sufficient stabilization, protect mediastinal organs and prevent ventilation disorder.

The stability of thorax wall is required for physiological respiratory function, and in the cases with broad wall defects, the reconstruction must be supported with rigid structures. The full-layer resection and reconstruction of chest wall still remain as one of the most difficult operations. Many techniques and materials have been used for the reconstruction so far.<sup>[1]</sup> We recommend the sternal reconstruction technique that we performed with avascular autologous fibula graft and metal plates for such cases.

### Case Report

A 74-year-old male case exposed to a mitral valve replacement seven months ago had developed an open injury in the mid-line sternotomy one month after the operation, and purulent discharge had started. The patient was treated with antibiotics and medically treated at the external center for about 6 months. He applied to our clinic for treatment. On admission, fatigue and anemic appearance were detected in the case, and four sinuses were also filled with purulent discharge in the mid-line sternotomy. In his blood analysis, the case with heart failure hypertension and insulin-dependent diabetes mellitus (DM) in his history showed the following: white blood count (WBC) 13.79 K/ $\mu$ L, rate of neutrophils 74.8% (higher), hemoglobin (Hgb) 9.6 g/dL (lower) and C-reactive protein (CRP) and 25.2 mg/L (higher). On thoracic computed tomography (CT), an appearance consistent with osteomyelitis was determined on the anterior aspect of sternum (Fig. 1). As a result, the case

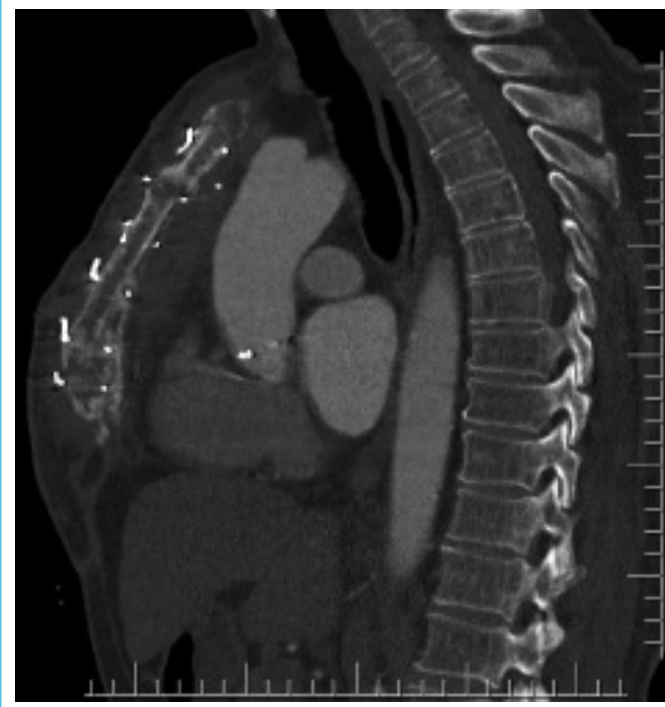**Address for correspondence:** Serdar Ozkan, MD. Medova Hastanesi, Gogus Cerrahisi Klinigi, Seyh Samil Mahallesi, Dosteli Caddesi, No: 52/1, Selcuklu, Konya, Turkey

**Phone:** +90 506 533 99 79 **E-mail:** drozkan78@yahoo.com

**Submitted Date:** June 01, 2018 **Accepted Date:** July 31, 2018 **Available Online Date:** October 10, 2018

©Copyright 2018 by Eurasian Journal of Medicine and Oncology - Available online at [www.ejmo.org](http://www.ejmo.org)



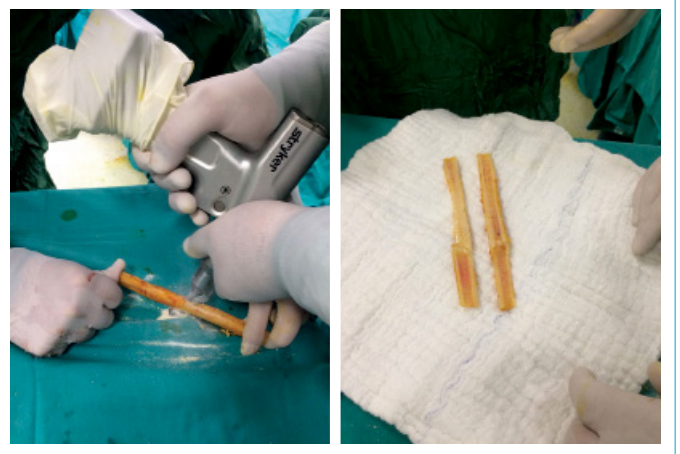


**Figure 1.** Computed tomography appearance of preoperative sternum.

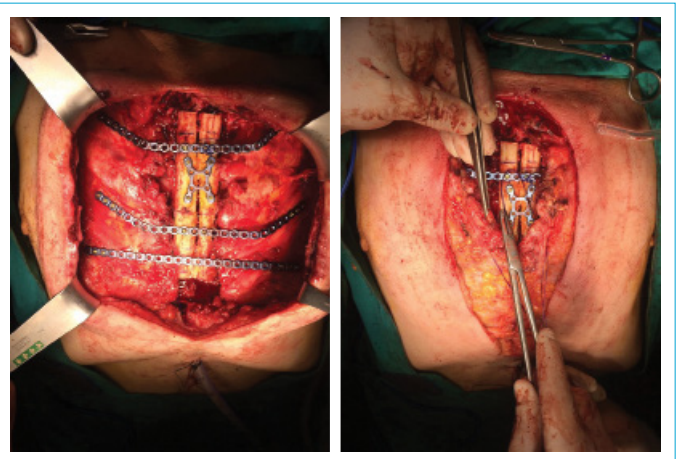
was hospitalized by planning the sternum resection and the reconstruction of anterior thorax wall. According to the results of antibiogram isolate (*klebsiella pneumoniae*) obtained from the injury discharge, the treatment regime (vankomycin and meropenem) was commenced.

### Surgical Technique

For providing a sufficient stabilization to protect mediastinal structures and fill the potential gap to occur after the sternum resection, we decided to use an autologous fibula graft. As the first step, the sternum was reached with the re-incision through the mid-line sternotomy. Also, we saw that the bone structure was quite distorted, and there was dehiscence in the mid-line sternotomy. Except for a quarter of the proximal manubrium sterni, the whole sternum was resected in a way to protect sternoclavicular joints. The bone tissue was revealed by scratching the anterior surface suspected to be infected with a rongeur in the remaining surface of the manubrium. In addition, intense inflammation and a tissue injury secondary to infection were observed in pericardiac areas, pericardium, pleura and surrounding soft tissues. These structures were strived to be debrided with curettage until reaching the hemorrhagic tissues. Following the debridement, the mediastenum was irrigated with povidone iodine and solutions including antibiotics. The remaining part of the manubrium sterni was irrigated two or three times with the aqueous solution of hydrogen per-



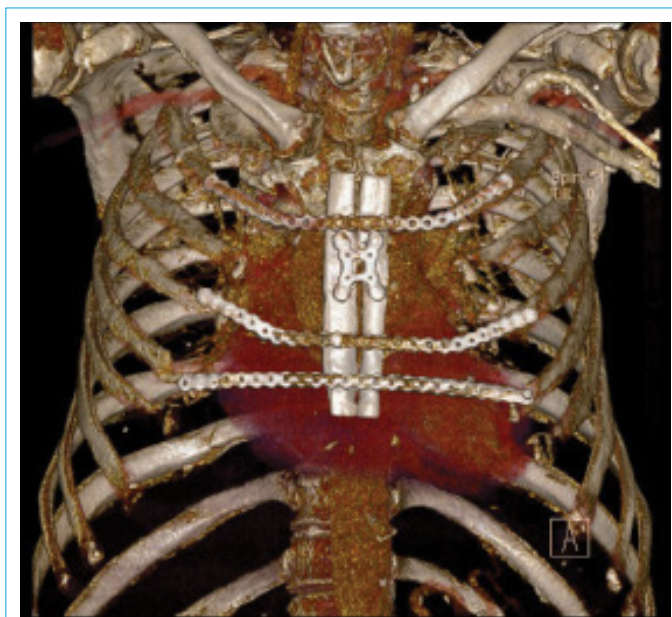**Figure 2.** Preparation phase of autologous fibula graft.



**Figure 3.** Placement of a combination of autologous fibula graft and metal plaque on the anterior chest wall and completion of reconstruction with bilateral pectoral muscle flap.

oxide. By measuring the reconstruction area, the length of fibula graft was determined, and so an avascular fibula-free graft of 13 cm was removed from the distal of the patient's left lower extremity. By cutting the removed free graft along its long axis with a sternotomy saw, the free graft was divided into two segments (Fig. 2). After the necessary measurements and marking in the reconstruction area, two-half pieces of the fibula were fixed side-by-side with the help of metal plates and prepared in a way to be fixed to the anterior thorax wall. The bone and metal prosthesis were fixed to the ribs with the help of screws, and the stabilization was obtained (Fig. 3). A silicon drainage tube was placed under the graft, and after the stabilization, bilateral muscles were prepared in the shape of flaps and pulled over the fibular grafts and plates in the thoracic anterior wall (Fig. 3).

On postoperative third day, a medical treatment was started due to cardiac arrhythmia. Because his cardiac rhythm returned to normal limits on fourth day, the case began



**Figure 4.** Postoperative thorax CT appearance.

to move and felt the need for defecation. On the third day after the withdrawal of the drainage tube in the mediastinum due to lack of drainage on postoperative fifth day, a lung radiography was taken to control the condition, and the graphy revealed a staging in the mediastinum. Upon the aspiration of seropurulent fluid after puncture biopsy, a drainage tube was placed in the mediastinum again, and mediastinal irrigation of 4x1 per day was commenced. For irrigation, the solutions with povidone iodine and rifampicin were used. The seropurulent fluid in the case was mediastinally irrigated for one week and observed to become serous. When major depressive symptoms were witnessed in the case on postoperative 15<sup>th</sup> day, the case was discharged with the mediastinal drainage tube. Following the withdrawal of the drainage tube on 35<sup>th</sup> day after the discharge, our case still maintains a healthy life for four months (Fig. 4).

## Discussion

Wound infections developing after sternotomy occur during nearly 21 days.<sup>[2]</sup> Although infections observed after sternotomy, such as mediastinitis, chronic condritis and osteomyelitis, are among rare entities, their outcomes are devastating, and the prevalence varies between 0.4–6.9% after operations. Despite the rarity of wound infections, the mortality rate ranges from 7 to 80% without surgical interventions.<sup>[3, 4]</sup>

Chronic obstructive pulmonary disease, DM, obesity, use of bilateral internal mammary arteries, cigarette smoking and duration of prolonged surgery or ventilation are among the potential perioperative risk factors leading to

sternal dehiscence and mediastinitis. Advanced age, female gender, type of cardiac surgeries, re-operation, treatment with steroids and mediastinal radiotherapy are defined as important risk factors. In addition, the use of bone wax or diathermy in large quantities are also reported as other preventable factors as wound healing.<sup>[5]</sup> Insulin-dependent DM and advanced age were evaluated as primary risk factors in our case.

Sternal infections are manifested with non-specific symptoms, such as fever, leukocytosis and chest pain, or with specific symptoms and findings, such as cellulite, chest tenderness, purulent discharge from the sternotomy line, sinuses with chronic discharge and sternal instability.<sup>[4]</sup> Our case had all of these symptoms, and the purulent discharge lasting for nearly six months was a sign of chronic infection.

In all of such infections, early debridement increases the chance of success. A delay in treatment causes the infection to extend further to the soft tissue and bone, making treatment more difficult. In addition, the delay also leads the infection to extend to mediastinum, tissues around the heart, grafts, stitching lines and prosthetic grafts, and so increasing morbidity.<sup>[4]</sup> The mediastinal staging and seropurulent fluid developing on postoperative 8<sup>th</sup> day in our case was a sign of chronic infection. The debridement performed in such cases for mediastinal soft tissues and bones cannot abolish the infected foci precisely and is most definite sign of the complications and therapeutic difficulties caused by the delay in treatment.

One to 5% of wound infections occurring after median sternotomy require re-operations, and the debridement and reconstruction with muscle or omental flaps are often carried out.<sup>[2]</sup> The first stage in the current treatment regimes of sternal infections and injuries is to bring infections under control with the wide debridement of wound orifices, including bones and cartilages.<sup>[3]</sup> The main target here is to remove foreign bodies, such as wires and stitches during the debridement and to debride the infected tissues until hemorrhagic bones or cartilages.<sup>[3, 4]</sup> The insufficiency of the debridement is the most important reason for the recurrence of widespread and chronic infections.

Many surgical techniques, including different materials, have been performed for the reconstruction of anterior chest wall and sternal replacement. Methyl methacrylate, polytetrafluoroethylene, marlex cage, metallic plates, bone-homograft and musculocutaneous flaps are among the most frequently used techniques. The use of prosthetic materials is the most common technique for the reconstruction of chest wall. Although widely available and easy to use, prosthetic materials may lead to various conditions, such as erosions in adjacent structures, obtaining inadequate support

and lack of tissue integrity due to their excessive toughness.<sup>[1]</sup> The identification of the ideal material for the reconstruction of chest wall still remains as a major problem.

The use of autograft or allograft bone is a viable solution in order to repair the small defects of thoracic wall.<sup>[6]</sup> An alternative for the reconstruction of the chest wall skeleton is an autologous bone graft preventing the use of foreign materials. Theoretically, autologous bone tissue is chosen due to lack of biologic tolerance problem.<sup>[6]</sup>

The skeletal stability of the chest wall was previously performed through many vascular grafts (autologous and heterologous) and prosthetic materials.<sup>[7]</sup> Among autologous grafts, avascular bones, such as ribs, tibia, iliac crest and fibula, were used to reconstruct the chest wall.<sup>[6]</sup>

The transfer of free autologous fibula is commonly used in the long bone and mandibular reconstructions.<sup>[7]</sup> Due to the periosteal blood circulation of the fibula shaft, many sections can be formed in different lengths by osteotomizing. In addition, thanks to its structure, the fibula is a strong cortical bone keeping the screws and wires together tightly.<sup>[7]</sup> Fibula flap has become one of the most commonly used vascularized osseous and osteocutaneous flaps for the reconstruction of body defects, particularly around the mandible, radius, femur and tibia, and can be osteotomized into many segments in different lengths and shapes.

In our case, in order to widen the surface area and use the graft more productively, we first separated the fibula axially into two, and then chose to implant it by fixing side-by-side. Therefore, we both minimized loss of function and complication risks to occur in the extremity by taking the whole or a great segment of the fibula. We covered almost all of the surface by widening reconstruction area. Based on literature, we saw that the reconstruction of sternum through avascular free autologous fibula graft was not previously carried out as in our case, and so consider that our procedure is the first. We call the technique that we have developed as the "İpek method".

The advantages of autografts are the easy integration with the recipient bone, low infection risk and lack of rejection. However, as well as the insufficient amount of bone to be removed, potential complications developing in the grafting area may also be assessed as other disadvantages.<sup>[11]</sup> Bone autografts have optimal biomechanical properties, and are fully compatible. Bone grafts also serve as a skeleton for bone formation through osteoprogenitor cells.<sup>[11]</sup> As a primary disadvantage, the procedure of removing and using autologous bone is difficult and complex, if there is a major defect. However, this procedure may lead to aesthetic and functional loss in the area where the bone was taken. The reconstruction of thorax wall can include the constitu-

ents of both the skeleton and soft tissues. Muscle flaps are planned according to the prevalence of the infection and the extension of the defect. By incorporating well-bloody tissues into this area, muscle flaps will cause antibiotics to reach the area and wounds to heal swiftly.<sup>[8]</sup> In our case, we aimed at improving the amelioration and tissue support by covering the graft with bilateral pectoral muscle flap after implanting bone graft.

Thanks to the technique that we have described, the reconstruction of anterior thoracic wall after the sternal resection can be achieved in a healthier and stronger manner. We consider that the time of treatment and hospitalization will be shortened prominently in cases not accompanied by infections, e.g. sternal tumors, especially as in our case.

### Disclosures

**Informed Consent:** Written informed consent was obtained from the patient for the publication of the case report and the accompanying images.

**Peer-review:** Externally peer-reviewed.

**Conflict of Interest:** None declared.

### References

1. Marulli G, Hamad AM, Cogliati E, Breda C, Zuin A, Rea F. Allograft sternochondral replacement after resection of large sternal chondrosarcoma. *J Thorac Cardiovasc Surg* 2010;139:e69–70.
2. Karamese M, Akdağ O, Ünal Yıldırım G, Selimoğlu MN, Görmüş N, Tosun Z. Vacuum therapy and pectoralis major muscle flap combination in treatment of sternal infections: a case report. *Turk J Plast Surg* 2014;22:117–20.
3. Moor EV, Neuman RA, Weinberg A, Wexler MR. Transposition of the great omentum for infected sternotomy wounds in cardiac surgery. Report of 16 cases and review of published reports. *Scand J Plast Reconstr Surg Hand Surg* 1999;33:25–9.
4. Herrera HR, Ginsburg ME. The pectoralis major myocutaneous flap and omental transposition for closure of infected median sternotomy wounds. *Plast Reconstr Surg* 1982;70:465–70.
5. Grolitzer M, Wagner F, Pfeiffer S, Folkmann S, Meinhart J, Fischlein T, et al. A prospective randomized multicenter trial shows improvement of sternum related complications in cardiac surgery with the Posthorax support vest. *Interact Cardiovasc Thorac Surg* 2010;10:714–8. [\[CrossRef\]](#)
6. Szumniak R, Maciejewski A. The Use of Fibula Free Flap for Reconstruction of Anterior Chest Wall Full-Thickness Defects. *Open Journal of Thoracic Surgery* 2013;3:107–10. [\[CrossRef\]](#)
7. Cunha-Gomes D, Bhatena H, Kavarana N, Mistry R, Fakh A. A free fibula autologous transfer for a full-thickness anterior chest wall defect. *Eur J Plast Surg* 2001;24:140–3. [\[CrossRef\]](#)
8. Krabatsch T, Schmitt DV, Mohr FW, Hetzer R. Thoracic transposition of the greater omentum as an adjunct in the treatment of mediastinitis-pros and cons within the context of a randomised study. *Eur J Surg Suppl* 1999:45–8. [\[CrossRef\]](#)