



Research Article

Using a New Hand - Held Colposcope in Combination with Cryotherapy and LEEP in a See - and - Treat Cervical Cancer Screening Program

 Prachi N. Godiwala,¹  Amelia Goldstein,²  Tierney O'Keefe,³  Lena Goldstein,⁴  Karen O'Keefe,³
 Casey O'Keefe,⁵  Gall R. Goldstein,⁶  Andrew T. Goldstein^{1,7}

¹Department of Obstetrics and Gynecology, The George Washington University School of Medicine and Health Sciences, Washington DC

²Duke University, Durham, North Carolina

³Bellingham Bay Family Medicine, Bellingham, Washington

⁴Yale University, New Haven, Connecticut

⁵Pacific Northwest Urology Specialists, Bellingham, Washington

⁶Annapolis Dermatology Center, Annapolis, Maryland

⁷The Center for Vulvovaginal Disorders, DC, Washington

Abstract

Objectives: To screen and treat women in a low-resource area of the Amazon basin in Peru for cervical cancer using a hand-held digital colposcope and compare the colposcopic impressions and histologic diagnoses.

Methods: Descriptive study of 250 Peruvian women who presented for visualization with acetic acid (VIA) screening in the Amazon basin during October 2017. Screening was performed using a digital handheld colposcope system, with biopsies collected and analyzed for those who were thought to have cervical dysplasia on colposcopic impression. The primary outcome was the congruence between colposcopic impression and pathologic diagnosis on cervical biopsy.

Results: 250 women were screened. 30 women screened positive during colposcopy. Of the 20 women who were suspected of having low-grade dysplasia, 15 had CIN 1 and 5 were negative for dysplasia (75% congruent, CIN1). Of the 6 women suspected of having high-grade dysplasia, 1 had cervicitis, 2 had CIN2, and 3 had CIN3 (83.3% congruent, CIN2-3). Of the 4 women suspected of having invasive carcinoma, 3 had invasive cancer and one had severe cervicitis (75% congruent, cervical carcinoma).

Conclusion: Digital colposcopy can optimize cervical cancer screening in low resource settings, as it can yield a relatively high congruence between colposcopic impressions and histologic diagnosis.

Keywords: cervical dysplasia, colposcopy, digital, mobile, see-and-treat, visualization with acetic acid (VIA)

Cite This Article: Godiwala PN, Goldstein A, O'Keefe T, Goldstein L, O'Keefe K, O'Keefe C, Goldstein AT. Using a New Hand - Held Colposcope in Combination with Cryotherapy and LEEP in a See - and - Treat Cervical Cancer Screening Program. *EJMO* 2019;3(4):257–262.

The International Agency for Research on Cancer has estimated that there were 528,000 new cases of cervical cancer and 266,000 deaths due to cervical cancer in 2012.^[1] Of these cases, 85% of cases worldwide and 87% of deaths

related to cervical cancer are seen in low and middle-income countries largely secondary to inadequate screening for the disease.^[2] The robust cervical cancer screening and prevention programs via Papanicolaou (Pap) testing

Address for correspondence: Prachi N. Godiwala, MD. Department of Obstetrics and Gynecology, The George Washington University School of Medicine and Health Sciences, Washington DC

Phone: +508 340-0179 **E-mail:** prachi.godiwala@gmail.com

Submitted Date: July 27, 2019 **Accepted Date:** September 19, 2019 **Available Online Date:** November 13, 2019

©Copyright 2019 by Eurasian Journal of Medicine and Oncology - Available online at www.ejmo.org

OPEN ACCESS This work is licensed under a Creative Commons Attribution-NonCommercial 4.0 International License.



and colposcopy that are used in developed nations has been estimated to reduce the incidence of cervical cancer by 80% in these high resource settings.^[3] However, these programs are not always possible to implement in lower-resource countries due to multiple factors, including lack of appropriate follow up of results, lack of trained cytopathologists leading to a high rate of false negative results, and the prohibitive cost of organizing such programs.^[4, 5]

The incidence of cervical cancer in Peru differs depending on the geographical location due to varying risk factors and exposure to varied environmental factors. For example, the national incidence of invasive cervical cancer in Peru is 37.2 new cases per 100,000 women annually. However, the rate is 19.2 cases per 100,000 women in the urban capital of Lima based on the Metropolitan Cancer Registry, whereas the Cancer Registry of Trujillo, which collects data from the more rural northern part of the country, confirms a much higher incidence of 43.2 new cases per 100,000 women annually in this region. The discrepancy in incidence rates between the highly educated urban areas and the remote rural areas highlight the socio-economic, access, and cultural disparities between the two populations in question.^[6] This rate may also be influenced by the lack of trained cytopathologists in Peru. In fact, in a study of 5,435 Peruvian women, the sensitivity of a diagnosis of cervical carcinoma in situ based on cervical cytology was only 42.5%.^[5]

For these reasons, a recommended approach to screen for cervical cancer in low-resource settings in Peru is with visual inspection with acetic acid (VIA) or visual inspection with Lugol's iodine (VILI).^[4] Traditional VIA combines visual inspection of the cervix without the aid of a colposcope after the application of acetic acid. VIA is frequently performed in a "see-and-treat" regimen in which VIA positive women are immediately treated with either cryotherapy or loop electrosurgical excision procedure (LEEP). Biopsies may be obtained, but the treatment is completed prior to histologic examination of the specimens; this data can be used to retroactively categorize the level of dysplasia or guide further treatment. This sequence allows for patients to be both screened and treated at the same visit to limit the very real risk of patients being lost to follow up.^[4]

The quality of traditional VIA can be affected by numerous elements: poor visual acuity of the examiner, the inability to magnify images to visualize irregularities in the cervical tissue, a dim light source, and inadequate training of providers. Due to these factors, it is very difficult to monitor quality control of the VIA program in see-and-treat protocols that do not obtain documented images of the cervical exam or confirmatory pathology.^[7] In this study, instead of using traditional VIA, cervixes were examined after the

application of acetic acid with a new handheld, highly portable, digital colposcope. This mobile colposcope combines a high lumen LED light source, a high quality optical magnifying lens, and the advanced digital optics found in Android based smartphones (Fig. 1). The primary goal of this project was to screen and treat women of the Amazon basin in Peru for cervical cancer and dysplasia using a see-and-treat protocol using a hand-held digital colposcope. We hypothesized that by replacing traditional VIA with digital colposcopy we would be able to improve visualization of the cervixes. We aimed to use magnification of the high quality digital images to form accurate colposcopic impressions that could guide treatment without the aid of a pathologic diagnosis, which is not generally available in this remote region. We hypothesized that there would be a high rate of congruence between the colposcopic impressions and the histologic diagnoses once biopsies collected at the time of colposcopy were later analyzed.

Methods

The purpose of this study was to screen and treat women in remote communities on the periphery of Iquitos, Peru in the Amazon basin for cervical dysplasia and cancer. Screening was performed in October 2017 using a digital handheld colposcope (EVA™ system, MobileODT, Israel). Amazon Promise, a local NGO that partners with governmental health clinics, identified communities that had

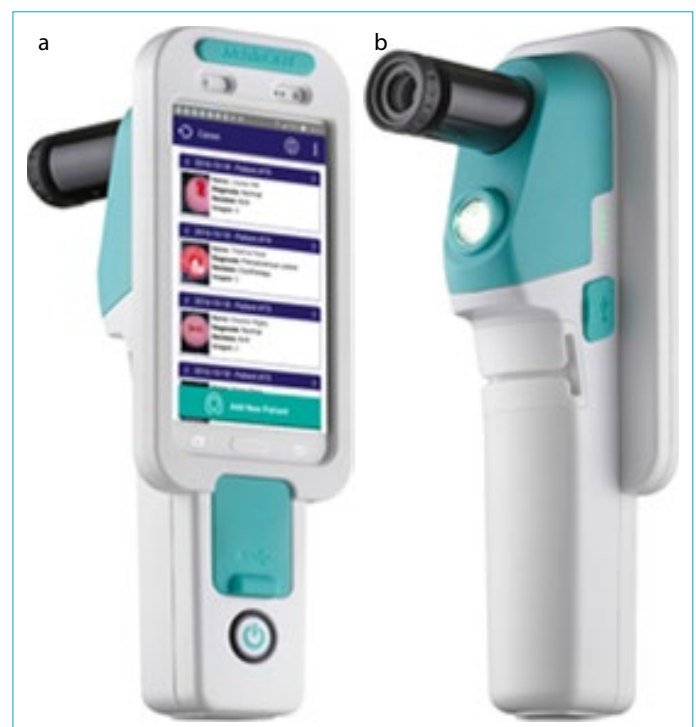

Figure 1. EVA™ system. (a) Front view of EVA™ system and CervDx application. (b) Back view of EVA™ system.

not been previously screened. Patients were screened on a first come, first served basis. Screening was carried out by one of five providers including an ASCCP-certified colposcopist, and consisted of a speculum examination followed by the application of 5% acetic acid solution to the cervix for 2 minutes. The cervix was then visualized with the colposcope mounted on a lightweight tripod for stability, and digital colposcopic images (DCs) were obtained. The DCs were uploaded to a cloud-based medical record using an application on the smartphone that pairs with the colposcope (CervDx) to organize data. All images were reviewed on a smartphone at the time of colposcopy by the ASCCP certified colposcopist (ATG) for quality control.

Positive results were defined as abnormal acetowhite lesions, punctations, mosaicism, hypervascularity, or obvious growths from the cervix with acetowhite staining. The positive results were categorized into probable low-grade dysplasia (likely CIN1), probable high-grade dysplasia (likely CIN2-3), or probable invasive cancer. Representative lesions of low grade dysplasia (CIN1), high grade dysplasia (CIN3), and cervical cancer are depicted in Figures 2, 3, and 4, respectively. All patients with positive results had two separate cervical biopsies collected using biopsy forceps in the abnormal-appearing tissue to ensure quality control, using the hand-held colposcope for magnification during biopsy collection. Biopsies were only per-

formed on women with suspected low-grade dysplasia, high-grade dysplasia, or invasive cancer.

Treatment for those with suspected low-grade dysplasia consisted of cryotherapy. Cryotherapy was performed us-

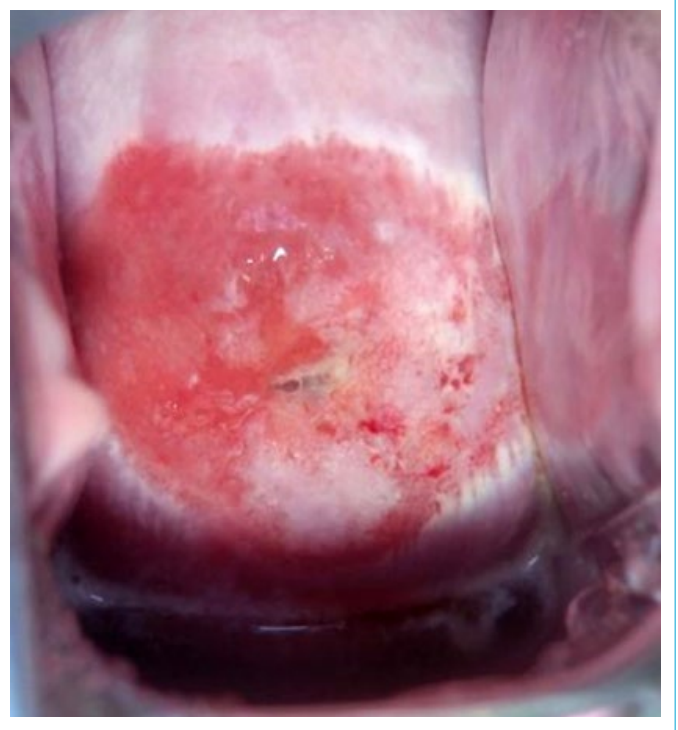

Figure 3. Digital cervicograph showing CIN3.

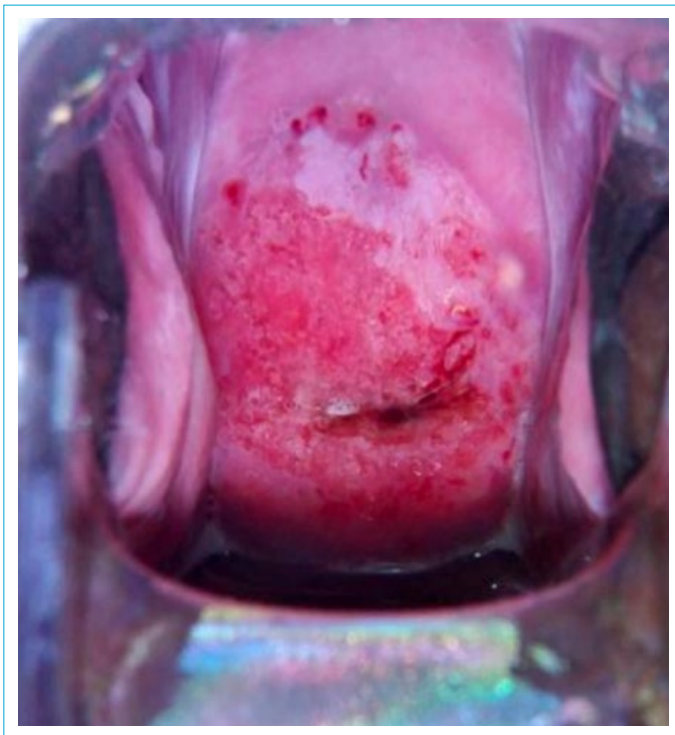


Figure 2. Digital cervicograph showing CIN1.

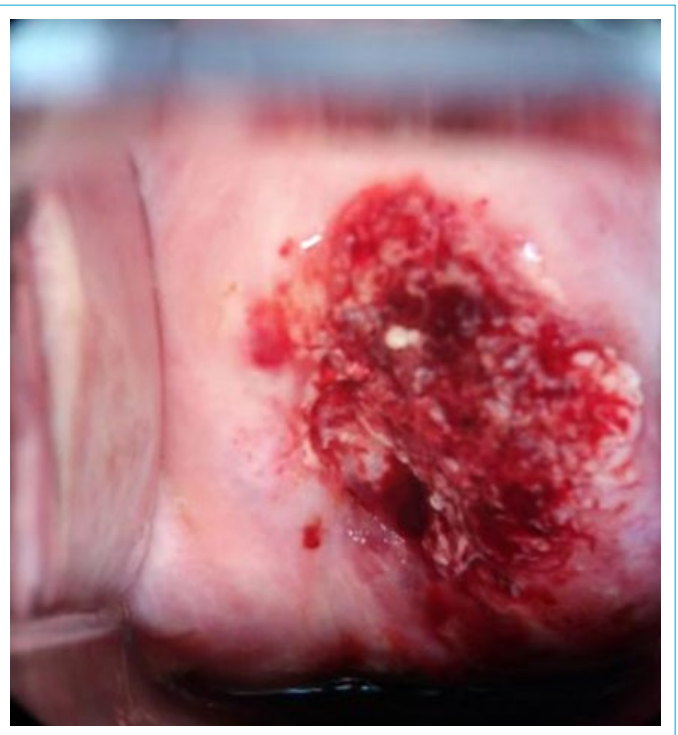

Figure 4. Digital cervicograph showing cervical cancer.

ing CO₂ gas and a cryotherapy tip that was appropriate to the patient's lesion. All cryotherapy was performed according to WHO guidelines with a 3-minute freeze, a 5-minute thaw, and then another 3-minute freeze of the cervix.^[8] Women with probable high-grade lesions had a LEEP performed according to WHO guidelines.^[9] Women with suspected invasive cancer had biopsies collected, but no ablative or excisional procedure performed. All cervical biopsies and LEEP specimens were analyzed in the United States by board certified pathologists without knowledge of the colposcopy results. The biopsy specimens were evaluated with traditional hematoxylin and eosin stains and P16 and Ki67 immunostains.

Those with confirmed invasive cancer were referred to a gynecologic surgeon at the regional hospital for radical hysterectomy and/or radiation therapy.

All participants signed a consent to research at the time of initial screening. This study was approved for research on human subjects by Advarra IRB (IRB number Pro00025298).

Results

A total of 250 women were screened, and of these, 30 women screened positive using both VIA and the handheld colposcope. In approximately 12% of the colposcopies the transformation zone was not visualized and these were categorized as inadequate. The mean age of the patients with positive screening results was 35.0 (SD 9.6, n=29). The average gravidity was 3.7 (SD 2.4, n=27) and the average parity was 2.9 (SD 1.8, n=27).

Twenty of these thirty women were suspected of having low-grade dysplasia, and upon analysis of their cervical biopsies, 15 women had pathology-confirmed CIN1 and 5 were negative for dysplasia. Six women were suspected to have high-grade dysplasia, and pathology confirmed that 2 of these had CIN2, 3 had CIN3, and 1 had cervicitis. Of the 4 women suspected of having invasive carcinoma, 3 had invasive cervical cancer and one had severe cervicitis. These results are summarized in Table 1.

Discussion

A study from Shahida and colleagues examined the congruence between colposcopic impression and histologic diagnosis of cervical biopsies.^[10] In this study, women were first screened with VIA, and those with positive VIA results were referred for colposcopy with a traditional colposcope. In their study, among 79 women with impression CIN1 on colposcopy, 22.8% cases were chronic cervicitis, 69.6% were CIN I, and 7.6% were CIN2-3 on histology. Among 38 women with impression CIN2-3 on colposcopy, 7.8% were found to chronic cervicitis, 31.6% were CIN1 and 60.5% were CIN2-3 on histology. In their study, women were required to participate in a two-step process, as they first had to complete VIA and then, if positive, have colposcopy performed. In our study, the rates of congruence between the colposcopic impression and histology were higher using the digital colposcope as compared to Shahida et al's two-step process.

Luciani et al. used VIA in a low-resource area of Peru in the late 2000s to examine the prevalence of high-grade dysplasia and invasive cervical cancer in women who were previously screened by VIA (4252 women) compared with those who had not been previously screened (4392 women). They found lower rates of dysplasia and cancer as compared to our study. In their study, histologically confirmed CIN2 or worse was diagnosed in 0.7% of previously screened women and 2.6% of previously unscreened women. Histologically confirmed invasive cervical cancer was diagnosed in 4 women (0.09%) of those previously screened and in 43 women (1.00%) of those not previously screened.^[11] Our rate of pathology-confirmed high-grade dysplasia were on par with these numbers, and our rate of cervical cancer was slightly higher than this number, signifying that our results are congruent with past studies conducted in this region.

Our study had notable strengths. While multiple providers were involved in the initial screening, quality control was assured by the review of all digital colposcopic images by the supervising gynecologist. As such, this oversight likely

Table 1. VIA and Pathology Results

	VIA Impression	Pathology-confirmed diagnosis	% Congruence between impression and pathology	Prevalence rate/100000 by pathology (%)
Normal	220	NA	NA	NA
Low-grade dysplasia	20	15	75	6000 (6.0)
High-grade dysplasia	6	5	83.3	2000 (2.0)
Invasive cancer	4	3	75	1200 (1.2)
Total	250	30	76.7	9200 (9.2)

NA: not applicable.

limited false negative results. In addition, US-based board-certified pathologists evaluated all of the biopsy specimens.

Our study also had important limitations. The sample size of 250 was small, although the rates of dysplasia and cancer as noted above were comparable to previous data sets. This study may also be subject to selection bias, as the population of women screened may not accurately reflect a true cross section of women in the region. For example, women may have been motivated to attend screening for reasons other than cervical cancer screening such as symptoms of vaginal discharge or bleeding, which may raise this population's probability of having a positive result due to potentially increased number of sexual partners or abnormal or postmenopausal vaginal bleeding. We also were unable to obtain accurate data about previous VIA or Pap screening in our patient population, which can drastically affect the prevalence of dysplasia; however, upon review of incomplete self-reported data, the number of women who had been previously screened was very low. There was a small percentage of inadequate colposcopies, which may have resulted in categorizing these women as either false positives or false negatives. In these select cases, we recommend performing endocervical curettage biopsy without performing cryotherapy or LEEP treatment at the time of initial colposcopy, with appropriate counseling instructing patients to follow up for care if needed after biopsy results return. Random biopsies on patients with negative colposcopic impressions were also not performed so internal validity was unable to be assessed in this study.

The most significant aspect of this study, however, was the addition of portable digital colposcopy in this see-and-treat cervical cancer screening program. The digital colposcope allowed for magnified visualization of surface morphology and gave us the ability to differentiate between CIN1 and CIN2-3 lesions at the time of initial visualization. As such, digital colposcopy was superior to VIA, which does not differentiate between low grade and high-grade lesions and instead only yields a "positive" or "negative" result. This differentiation enabled us to treat low-grade lesions with cryotherapy, which generally has a lower complication rate than LEEP. More importantly, however, this differentiation allowed us to treat the CIN2-3 lesions with LEEP, which offers a lower recurrence rate in high-grade dysplasia than treatment with cryotherapy.^[9] While the WHO currently recommends either cryotherapy or LEEP for CIN2-3, it acknowledges that this recommendation is based on low quality or very low quality data [9]. It is possible that this new data, if confirmed in larger studies, may alter this recommendation.

An improvement to this algorithm may be to include human papillomavirus (HPV) DNA testing and only perform digital colposcopy on women positive for high-risk HPV. HPV testing has shown promise as a primary screening method to detect cervical cancer as it has an extremely high sensitivity as well as a high negative predictive value in studies in the developed world.^[12] Swabs can be collected by either a health care provider or a patient collected by self-swab. In a study by Almonte of over 5,000 Peruvian women tested with VIA, liquid-based cytology, conventional cytology, and HPV DNA testing, HPV screening overall outperformed the other methods of screening, with a sensitivity of 95.8% of detecting of all carcinomas in situ or worse, with very low inadequacy rates (0.1%). HPV testing was inferior to VIA in only one category, detection of moderate to severe dysplasia, with a sensitivity of 59.6% at detecting CIN2-3 while VIA performed slightly better at 67.5%.^[4]

Unfortunately, HPV testing can still be difficult to implement in a low-resource setting, as the equipment needed to run this diagnostic test is costly and is not easily transported. For example, the careHPV system (Qiagen, Maryland) was developed with a grant from the PATH Foundation to be used in resource-poor countries. The careHPV system can run 90 specimens in approximately 3 hours, which is ideal for a see-and-treat screening program. However, the careHPV system still costs approximately US \$20,000 and each test costs approximately US \$8 per person if sampled by a clinician.^[13] In addition, the system weighs approximately 20 kilograms, and requires a trained technician and stable power supply to function. As such, the resources necessary to implement HPV testing are still not currently available in remote regions such as where screening was performed in this study. Indeed, the aforementioned Peruvian study by Almonte did not run these HPV samples in the field, but instead had these samples analyzed in London, UK; this delay in sample analysis would not be useful in a see-and-treat protocol. In the future, as more resources become available, primary HPV screening followed by digital colposcopy will likely improve both the sensitivity and specificity of cervical cancer screening in low-income countries.

Digital colposcopy has the potential to be superior to VIA as it can not only distinguish between low-grade and high-grade lesions, but it also can be easily used for patient care through telemedicine, to share knowledge about a patient's cervical examination between providers, and to provide permanent documentation in the patient's medical record. In addition, DCs can be used in medical education to facilitate training of providers to perform mobile colposcopy and interpret the results that they obtain, and to provide a method of quality control of screening with-

out adding significant time or costs to cervical dysplasia/cancer screening.

Conclusion

While see-and-treat cervical cancer screening protocols with VIA have become the standard of care in resource poor settings, limitations of VIA have been well documented. New technologies, such as the handheld colposcope used in this study, have the potential to eliminate the deficiencies of VIA previously mentioned and can provide additional information during the screening process that can be useful to guide treatment. In this study, we found that there was a high rate of congruence between colposcopic impression using a mobile digital colposcope and the histologic diagnosis. Clearly, the potential of this new technology and the results of this study suggest that further research is needed to explore see-and-treat protocols using a digital handheld colposcope.

Disclosures

Peer-review: Externally peer-reviewed.

Conflict of Interest: Andrew Goldstein is the president of the Gynecologic Cancers Research Foundation which provided the funding for this study.

Authorship Contributions: Concept – P.N.G., A.G., T.O., L.G., K.O., C.O., G.R.G., A.T.G.; Design – P.N.G., A.G., T.O., L.G., K.O., C.O., G.R.G., A.T.G.; Supervision – A.T.G.; Materials – A.T.G.; Data collection &/or processing – P.N.G., A.G., T.O., L.G., K.O., C.O., G.R.G., A.T.G.; Analysis and/or interpretation – P.N.G., A.G., T.O., L.G., K.O., C.O., G.R.G., A.T.G.; Literature search – P.N.G., A.T.G.; Writing – P.N.G., A.T.G.; Critical review – P.N.G., A.G., T.O., L.G., K.O., C.O., G.R.G., A.T.G.

References

1. Olson B, Gribble B, Dias J, et al. Cervical cancer screening programs and guidelines in low- and middle-income countries. *Int J Gynaecol Obstet* 2016;134:239–46. [\[CrossRef\]](#)
2. Gallay C, Girardet A, Viviano M, et al. Cervical cancer screening in low-resource settings: a smartphone image application as an alternative to colposcopy. *Int J Womens Health* 2017;9:455–61. [\[CrossRef\]](#)
3. Almonte M, Ferreccio C, Gonzales M, et al. Risk factors for high-risk human papillomavirus infection and cofactors for high-grade cervical disease in Peru. *Int J Gynecol Cancer* 2011;21:1654–63. [\[CrossRef\]](#)
4. Sankaranarayanan R. Screening for cancer in low- and middle-income countries. *Ann Glob Health* 2014;80:412–7. [\[CrossRef\]](#)
5. Almonte M, Ferreccio C, Winkler JL, et al. Cervical screening by visual inspection, HPV testing, liquid-based and conventional cytology in Amazonian Peru. *Int J Cancer* 2007;121:796–802.
6. Aguilar A, Pinto JA, Araujo J, et al. Control of cervical cancer in Peru: Current barriers and challenges for the future. *Mol Clin Oncol* 2016;5:241–5. [\[CrossRef\]](#)
7. Parashari A, Singh V. Reasons for variation in sensitivity and specificity of visual inspection with acetic acid (VIA) for the detection of pre- cancer and cancer lesions of uterine cervix. *Asian Pac J Cancer Prev* 2013;14:7761–2. [\[CrossRef\]](#)
8. WHO Guidelines: Use of Cryotherapy for Cervical Intraepithelial Neoplasia. Geneva: World Health Organization; 2011.
9. WHO Guidelines for Treatment of Cervical Intraepithelial Neoplasia 2–3 and Adenocarcinoma in situ: Cryotherapy, Large Loop Excision of the Transformation Zone, and Cold Knife Conization. Geneva: World Health Organization; 2014.
10. Shahida SM, Mirza TT, Saleh AF, Islam MA. Colposcopic evaluation of pre-invasive and early cervical carcinoma with histologic correlation. *Mymensingh Med J* 2012;21:200–6.
11. Luciani S, Munoz S, Gonzales M, Delgado JM, Valcarcel M. Effectiveness of cervical cancer screening using visual inspection with acetic acid in Peru. *Int J Gynaecol Obstet* 2011;115:53–6.
12. Ditzian LR, David-west G, Maza M, Hartmann B, Shirazian T, Cremer M. Cervical cancer screening in low- and middle-income countries. *Mt Sinai J Med* 2011;78:319–26. [\[CrossRef\]](#)
13. Shi JF, Chen JF, Canfell K, et al. Estimation of the costs of cervical cancer screening, diagnosis and treatment in rural Shanxi Province, China: a micro-costing study. *BMC Health Serv Res* 2012;12:123. [\[CrossRef\]](#)